


































BELLA SMITH

| | | |
|-------------------------|------------------|-----------------------------|
| OWNER: SARAH SMITH | Hospital Name | REPORT ID: 15423 |
| SPECIES: CANINE | Hospital Address | DATE OF RECEIPT: 2020-06-09 |
| BREED: SPRINGER SPANIEL | | |
| GENDER: F | | |
| AGE: 10 YEARS | | |
| PATIENT ID: 18604 | | |









Services Rendered: SignalCARE™ SignalRAY™

Tests

| | Confidence |
|------------------------------------|---|
| Hip Dysplasia |  |
| Spondylosis |  |
| Thoracolumbar Disc Space Narrowing |  |
| Shoulder Arthropathy |  |
| Vertebral Heart Score |  |
| Bronchointerstitial Pattern |  |
| Renal Mineralization |  |
| Stifle Effusion |  |
| Two Populations of Small Intestine |  |
| Aggressive Bone Lesion |  |
| Appendicular Bone Fracture |  |
| Bronchial Pulmonary Pattern |  |
| Caudodorsal Parenchymal Pattern |  |
| Cervical Disc Space Narrowing |  |
| Colonic Foreign Material |  |
| Cranioventral Parenchymal Pattern |  |
| Diffuse Parenchymal Pattern |  |
| Esophageal Distension |  |
| Esophageal Foreign Body |  |
| Flattened Humeral Head |  |
| Gastric Dilatation and Volvulus |  |
| Gastric Distention |  |
| Gastric Foreign Material |  |
| Hepatomegaly |  |
| Mid Abdominal Mass |  |
| Nodular or Miliary Pattern |  |
| Patchy Interstitial Pattern |  |
| Pelvic Fracture |  |
| Peritoneal Fluid |  |
| Pleural Fluid |  |
| Pleural Gas |  |
| Pulmonary Mass(es) |  |
| Pulmonary Nodule |  |

BELLA SMITH

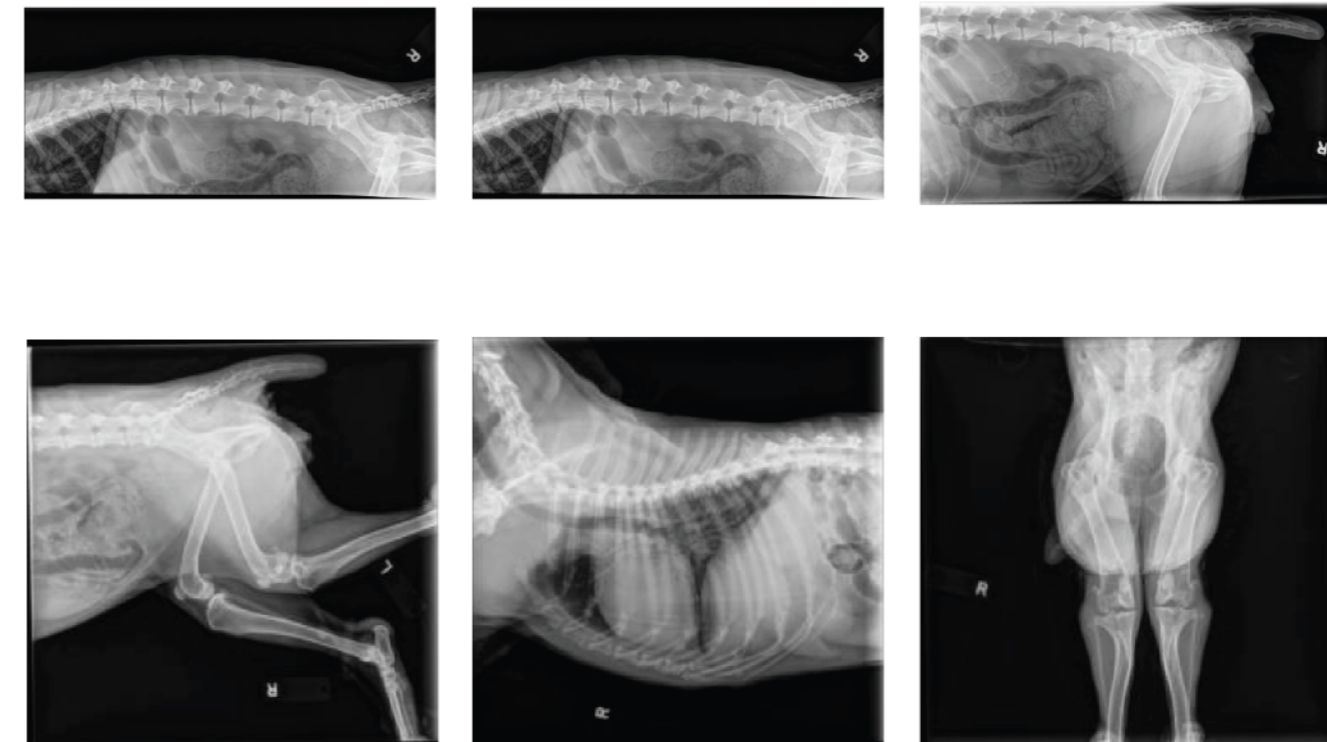
DATE OF RECEIPT: 2020-06-09

| | |
|-----------------------------------|---|
| Retroperitoneal Fluid |  |
| Retroperitoneal lymphadenopathy |  |
| Small Intestinal Foreign Material |  |
| Small Intestinal Plication |  |
| Small Kidney |  |
| Splenomegaly |  |
| Urethral calculi |  |
| Urinary Bladder Calculi |  |



Peter Walker, DVM

Radiology Images



These results were generated by computer assisted technology. Should a specific anatomy or condition not be listed that does not imply normal or abnormal, rather it could not be determined. Only a veterinarian can make a final diagnosis.